



RESENTING CLINICAL SIGNS

DATE History: Grade IV/VI systolic murmur. Asymptomatic.

9/23/21 **ECHOCARDIOGRAPHIC FINDINGS**
2D, M-mode, and Doppler study.

PERFORMED BY: There is moderate left atrial dilation. The mitral valve leaflets are thickened and exhibit systolic prolapse. A moderate jet of eccentric mitral regurgitation is present. There is moderate left ventricular dilation. Left ventricular systolic function is normal. The aorta and aortic valve are normal. Right atrial and right ventricular dimensions are normal. The tricuspid valve leaflets are thickened, and a mild jet of tricuspid regurgitation is present. TR velocity does not suggest the presence of pulmonary hypertension. The pulmonary artery and pulmonic valve are normal. No shunting lesions are visualized. No pericardial effusion or cardiac masses are seen.

INTERPRETED BY

Shari Reffi, CVT

Keith Blass, DVM,
MS, DACVIM
(Cardiology)

PATIENT

Curly Stewart
Beckanthal

LA - 34.2 mm
LVIDd - 34.4 mm
LVIDs - 20.5 mm
FS - 40.4%
LVOT - 1.06 m/s
RVOT - 0.89 m/s
TR - 2.78 m/s

ASSESSMENT/RECOMMENDATIONS

Degenerative mitral and tricuspid valve disease

SPECIES

Canine

This examination demonstrates regurgitation of blood across Curly's mitral and tricuspid valves resulting from degenerative valve disease. Curly's tricuspid valve disease is mild, and appears to be well-compensated at this time. His mitral valve disease is more advanced, as Curly has moderate mitral regurgitation present, with moderate secondary dilation of both his left atrium and left ventricle, though his left ventricular systolic function is well-preserved. Curly's mitral valve disease is still compensated, however, its severity indicates that he is at risk for the development of clinical signs, such as coughing, exercise intolerance, syncope, and labored breathing.

BREED

Cockapoo

SEX

I recommend starting Curly on pimobendan (2.5 mg BID), as this medication should help to slow the progression of his mitral valve disease.

MN

A recheck echocardiogram is recommended in 9 months. Thoracic radiographs are recommended if Curly experiences respiratory clinical signs.

AGE

12 y

WEIGHT

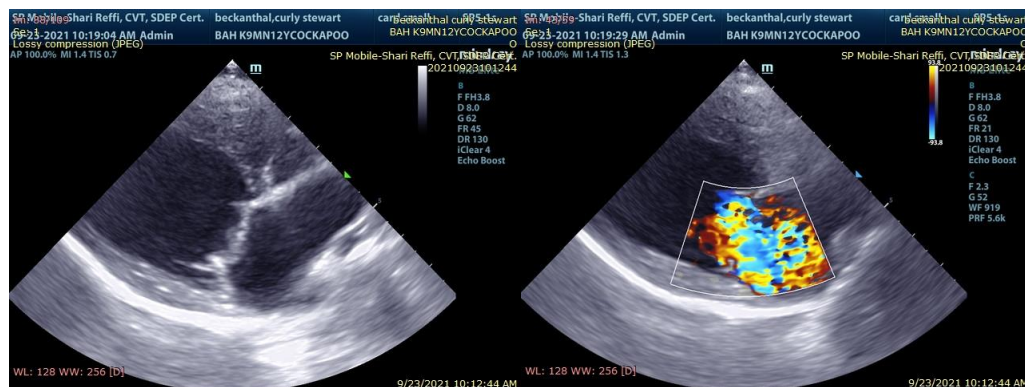
17 lb

HOSPITAL NAME

Blairstown AH

REFERRING VET

Dr. Zeliff





DATE

9/23/21

The information and recommendations provided are based on the images presented by the referring veterinarian. No evaluation can be communicated regarding pathology that was not visible in the image/video clips provided.

PERFORMED BY:

Thank you for this referral. If the clinical or image interpretation does not parallel your findings or if I can be of any further assistance please contact me.

Shari Reffi, CVT

INTERPRETED BY

Keith Blass, DVM, MS, DACVIM (Cardiology)

KeithBlass@gmail.com

631-804-5754

Keith Blass, DVM,
MS, DACVIM
(Cardiology)

PATIENT

Curly Stewart
Beckenthal

SPECIES

Canine

BREED

Cockapoo

SEX

MN

AGE

12 y

WEIGHT

17 lb

HOSPITAL NAME

Blairstown AH

REFERRING VET

Dr. Zeliff